

# A Case of Lichen Ruber Planus in a Patient with Familial Multiple Sclerosis

---

Sepčić, Juraj; Ristić, Smiljana; Perković, Olivio.; Brinar, Vesna;  
Lipozenčić, Jasna.; Crnić-Martinović, Marija; Starčević-Čizmarević, Nada;  
Labinac, J.; Kapović, Miljenko; Peterlin, B.

Source / Izvornik: **Journal of International Medical Research, 2010, 38, 1856 - 1860**

Journal article, Published version

Rad u časopisu, Objavljena verzija rada (izdavačev PDF)

<https://doi.org/10.1177/147323001003800533>

Permanent link / Trajna poveznica: <https://urn.nsk.hr/urn:nbn:hr:184:816404>

Rights / Prava: [Attribution-NoDerivatives 4.0 International](#)/[Imenovanje-Bez prerada 4.0 međunarodna](#)

Download date / Datum preuzimanja: **2024-07-28**



Repository / Repozitorij:

[Repository of the University of Rijeka, Faculty of Medicine - FMRI Repository](#)



# A Case of Lichen Ruber Planus in a Patient with Familial Multiple Sclerosis

J SEPČIĆ<sup>1</sup>, S RISTIĆ<sup>2</sup>, O PERKOVIĆ<sup>3</sup>, V BRINAR<sup>4</sup>, J LIPOZENČIĆ<sup>5</sup>, M CRNIĆ-MARTINOVIĆ<sup>6</sup>, N STARČEVIĆ ČIZMAREVIĆ<sup>2</sup>, D JANKO LABINAC<sup>7</sup>, M KAPOVIĆ<sup>2</sup> AND B PETERLIN<sup>8</sup>

<sup>1</sup>Department of Neurology, <sup>2</sup>Department of Biology and Medical Genetics, <sup>3</sup>Department of Neurology, and <sup>4</sup>Department of Transfusion Medicine, School of Medicine, University of Rijeka, Rijeka, Croatia; <sup>5</sup>Department of Neurology, and <sup>6</sup>Department of Dermatology, School of Medicine, University of Zagreb, Zagreb, Croatia; <sup>7</sup>Department of Neurology, General Hospital Pula, Pula, Croatia; <sup>8</sup>Division of Medical Genetics, Department of Obstetrics and Gynaecology, University of Ljubljana, Ljubljana, Slovenia

Multiple sclerosis and lichen ruber planus are clinically and histologically distinct complex disorders of putative autoimmune aetiology that are fairly commonly observed in isolation but rarely found in combination. Only two previous reports have described lichen skin disorders in association with multiple

sclerosis. The present report describes the case of a 51-year old Caucasian woman exhibiting both familial multiple sclerosis and lichen ruber planus. This combination may have occurred by chance or it might imply that these disorders share common mechanisms in their pathogenesis.

**KEY WORDS:** FAMILIAL MULTIPLE SCLEROSIS; LICHEN RUBER PLANUS; AUTOIMMUNE SKIN DISORDERS; CASE STUDY

## Introduction

Multiple sclerosis (MS) is a chronic disorder that exhibits focal demyelinated plaques and diffuse global injury of the central nervous system, particularly the brain.<sup>1</sup> Lichen ruber planus (LP), a subacute to chronic papulosquamous dermatose disorder, differentially affects the skin, mucous membranes, nails and hair.<sup>2</sup> Both MS and LP are clinically and histologically distinct complex disorders of putative autoimmune aetiology that are fairly commonly observed in isolation but rarely found in combination. The combination of these two disorders with altered immune regulation could facilitate the identification of contributing factors or reveal unexpected aspects of their aetiology

and pathogenesis. A link between autoimmune skin disorders and MS has been demonstrated in bullous pemphigoid,<sup>3,4</sup> however, there are only two previous reports describing lichen skin disorders associated with MS, one of which refers to cutaneous LP<sup>5</sup> and the other to lichen sclerosus.<sup>6</sup> A rare case of familial MS associated with LP is reported here.

## Case report

A 43-year old Caucasian female (body mass index 24 kg/m<sup>2</sup>) was first admitted to the Department of Neurology, School of Medicine, University of Rijeka, Rijeka, Croatia, in January 2000 with fatigue, monocular vision deterioration, and

numbness or tingling in the right leg and the face, in particular the lips. These disturbances had persisted for 3 – 4 days and were more pronounced in heated spaces. Neurological examination showed mild pyramidal syndrome on the right side and a normal fundus on both sides. Aside from slight C3-hypercomplementaemia (166 mg/dl), haemogram, blood chemistry, routine urinalysis and related tests were normal. Serology was negative for *Borrelia burgdorferi*, *Treponema pallidum*, hepatitis B, hepatitis C and human immunodeficiency virus. Isoelectrofocusing (IEF) assay of the cerebrospinal fluid demonstrated intrathecal synthesis of immunoglobulin (Ig)G (1.48 g/l; oligoclonal IgG bands positive-type 2 on IEF assay). Brainstem auditory and somatosensory evoked potentials were normal. Visually evoked potentials were delayed in both visual pathways, though predominantly the left.

On T<sub>2</sub>-weighted fast fluid-attenuated inversion-recovery brain magnetic resonance imaging (MRI), multiple periventricular and juxtacortical white matter lesions were revealed on both hemispheres and the right brainstem. Gadolinium-enhanced T<sub>1</sub>-weighted image showed several homogenous areas of enhancement on the left side of the centrum semiovale. Chest radiography showed no thymic tumour. A diagnosis of probable MS was established<sup>7</sup> and the patient was successfully treated with IV methylprednisolone (1 g/day for 5 days).

At age 50 years in October 2007 the patient was again hospitalized, this time at the Department of Neurology, School of Medicine, University of Zagreb, Zagreb, Croatia, with new neurological symptoms and signs: motor weakness of both lower limbs with slight spasticity and extensor plantar reflexes, particularly at the right

side, and absence of abdominal reflexes. Repeat MRI detected several new, oval, non-enhancing, demyelinating, T<sub>2</sub> hyperintense lesions of various sizes in the periventricular, paracortical and subcortical regions, predominantly in the frontal and parietal white matter of both cerebral hemispheres. Several minute, non-enhancing, demyelinating lesions were detected in the cervical spinal cord (C2 – C3). A diagnosis of definite MS was established<sup>7</sup> and the patient again was treated with IV methylprednisolone (1 g/day for 5 days). Her human leucocyte antigen [HLA] profile was: A\*02\*26; B\*39\*27; DRB1\*01\*16; DRB5\*01; DQB1\*0501\*0502. Also, the patient had a positive family history for MS – both a daughter and a second-degree female relative had clinically defined MS (HLA profile: A\*02\*31; B\*39\*35; DRB1\*15\*16; DRB5\*01; DQB1\*0502\*0603).

At age 51 years in January 2008, the patient presented at the Department of Dermatology, School of Medicine, University of Zagreb, with widespread purplish, minute, pruritic papules involving the skin of the thorax (upper back), abdomen, and flexural creases of the arms, elbows and lower legs. Linear excoriations and brownish pigmentation appeared on the flexor surfaces of the forearms. The lesions did not involve the nails, scalp, face, palms, soles, buccal and oesophageal mucosa or vulvovaginal area. These skin changes had been present since the spring of 1989 but were considered to be dermatitis. The patient had no metallic dental restorations or constructions, which can cause oral LP<sup>2</sup> and/or MS relapse.<sup>8</sup> Laboratory tests disclosed lymphocytosis (55%) and serum protein electrophoresis showed slightly increased  $\alpha_1$ - (4 g/l),  $\alpha_2$ - (8.5 g/l) and  $\beta$ -globulins (10.5 g/l). Antinuclear antibody was not detected by indirect

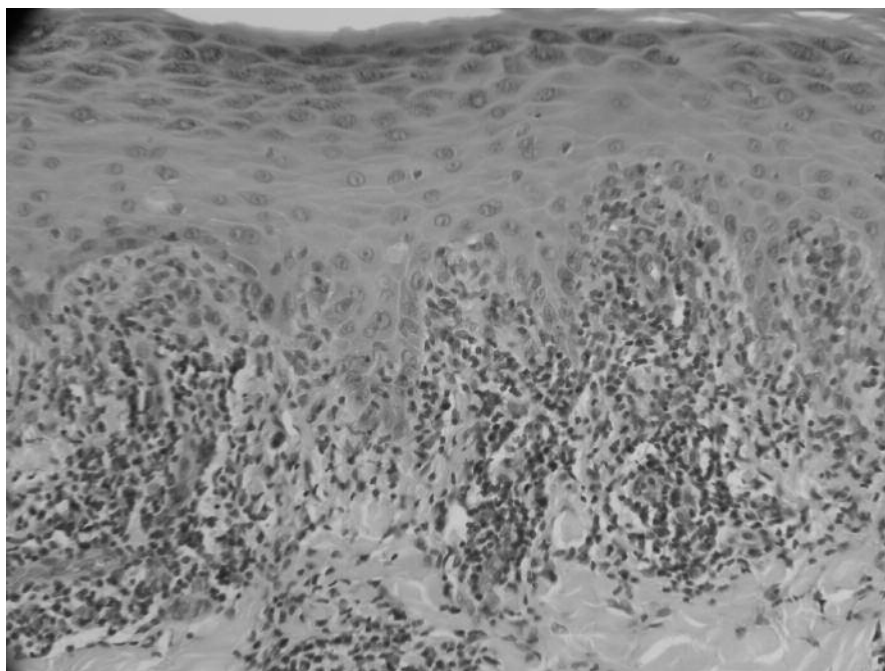
immunofluorescence. Histological analysis of a skin lesion biopsy revealed mild epithelial hyperparakeratosis, focal hypergranulosis, basal cell hydropic degeneration (liquefaction) and dense band-like mononuclear (lymphocytic and histiocytic) inflammatory infiltration immediately under an irregular acanthotic epidermis (Fig. 1). A diagnosis of LP was finally established<sup>2</sup> and the patient received oral antihistaminic agents (cetirizine dihydrochloride 10 mg/day for 15 days and loratadine 10 mg/day for 30 days) and topical steroids (betamethasone twice a day for 30 days) with partial efficacy. New lesions of the skin appeared after discontinuation of therapy.

In line with the Declaration of Helsinki, 1996, article II, written and signed informed consent was obtained from the patient for publication of this case report.

## Discussion

The patient described presented with two fairly common clinically and histologically distinct autoimmune disorders that affect tissues of ectodermal origin. The diagnoses of MS and LP met current diagnostic criteria.<sup>2,7</sup>

A link between autoimmune skin disorders and MS has been demonstrated in bullous pemphigoid;<sup>3,4</sup> however, there are only two previous reports describing lichen skin disorders associated with MS.<sup>5,6</sup> In analysing the deaths of 50 patients with LP,



**FIGURE 1:** Histopathological features of lichen ruber planus revealed mild epithelial hyperparakeratosis, focal hypergranulosis, basal cell hydropic degeneration (liquefaction) and dense band-like mononuclear (lymphocytic and histiocytic) inflammatory infiltration immediately under an irregular acanthotic epidermis (haematoxylin and eosin stain; original magnification  $\times 400$ )

Anonide and Reborá<sup>5</sup> found that autoimmune disorders, including ulcerative colitis, MS and primitive pulmonary sclerosis, were more common in patients with LP than those with psoriasis or in the general population. McGrath and Davies<sup>6</sup> reported a case of lichen sclerosus in the chronic wound of a patient with severe MS. The present case report is the third to show an association between lichen skin disorders and MS, and the first to describe LP associated with familial MS. This is noteworthy because both LP and MS have autoimmune characteristics and may, therefore, share some epidemiological, clinical and pathogenic factors that could help to clarify their aetiologies.

The prevalence of both MS and LP is higher in middle-aged adults, especially females and Caucasians, than in children and older adults.<sup>2,9</sup> Although not rigorously proven, several precipitating factors (viral infections, stress, medication, etc.) may interact to elicit the appearance of both these disorders.<sup>8,10</sup> Their clinical courses generally alternate between exacerbations and remissions, but LP relapses are not necessarily associated with MS relapses. Both disorders are frequently associated with vitiligo, alopecia areata, myasthenia gravis, ulcerative colitis, dermatomyositis, coeliac disease, acquired hypogammaglobulinaemia and other immune-related disorders.<sup>2,11</sup> Individuals with MS or LP may be genetically predisposed to cell-mediated immunity disorders which have abnormal T-lymphocyte responses to specific external antigens.<sup>6,12</sup> Indeed, both disorders respond to non-specific immunosuppressive drugs (corticotherapy, tacrolimus, alefacept) that

are known to be T-cell selective agents.<sup>13-15</sup> Both disorders also have genetic forms: several familial cases of LP have been reported,<sup>16</sup> and familial clustering of MS was first described in 1922.<sup>1,17</sup> The prevalence of MS and LP varies with geographical area, possibly indicating regional differences in genetic susceptibility.<sup>9,18</sup>

The present patient's family history included a daughter and second cousin with clinical MS. Although there is no strong consensus regarding the clustering of autoimmune disorders within MS probands and their families, numerous studies have shown an increased risk of autoimmunity in patients with MS and their first-degree relatives.<sup>19-22</sup> To date, several studies have described the possible coexistence of MS with autoimmune skin disorders, including pemphigoid,<sup>3,4</sup> pemphigus vulgaris,<sup>23</sup> scleroderma<sup>24</sup> and psoriasis.<sup>20</sup> This is the first reported case of both familial MS and LP occurring in a patient.

In conclusion, this is the third report of an association between MS and lichen skin disorders. This combination may have occurred by chance or it might imply shared mechanisms underlying their pathogenesis.

## Acknowledgements

We are grateful for the support provided by the Ministry of Science, Education and Sports of the Republic of Croatia (grant No. 062-1962766-0470). We are especially grateful to Dr Roger Pain for critically reading and revising the manuscript.

## Conflicts of interest

The authors had no conflicts of interest to declare in relation to this article.

• Received for publication 30 March 2010 • Accepted subject to revision 14 April 2010

• Revised accepted 29 July 2010

Copyright © 2010 Field House Publishing LLP

References

- 1 Lassmann H, Wekerle H: The pathology of multiple sclerosis. In: *McAlpine's Multiple Sclerosis* (Compston A, ed). Edinburgh: Churchill Livingstone, 2006; pp 598 – 599.
- 2 Marshman G: Lichen planus. *Australas J Dermatol* 1998; **39**: 1 – 13.
- 3 Venencie PY, Rosers RS, Schroeter AL: Bullous pemphigoid and malignancy: relationship to indirect immunofluorescent findings. *Acta Derm Venereol* 1984; **64**: 316 – 319.
- 4 Simjee S, Konqui A, Razaque-Ahmed A: Multiple sclerosis and bullous pemphigoid. *Dermatologica* 1985; **170**: 86 – 89.
- 5 Anonide A, Rebora A: What lichen planus patients die of. *Int J Dermatol* 1989; **28**: 524 – 526.
- 6 McGrath EJ, Davies MG: Lichen sclerosus arising from a chronic wound and coexistent with multiple sclerosis. *J Eur Acad Dermatol Venereol* 2005; **19**: 139 – 141.
- 7 Poser CM, Paty DW, Scheinberg L, *et al*: New diagnostic criteria for multiple sclerosis: guidelines for research protocols. *Ann Neurol* 1983; **13**: 227 – 231.
- 8 Compston A, Confavreux C: The environmental factor in multiple sclerosis. In: *McAlpine's Multiple Sclerosis* (Compston A, ed). Edinburgh: Churchill Livingstone, 2006; pp 105 – 111.
- 9 Compston A, Wekerle H, McDonald IW: The origin of multiple sclerosis: a synthesis. In: *McAlpine's Multiple Sclerosis* (Compston A, ed). Edinburgh: Churchill Livingstone, 2006; pp 273 – 284.
- 10 Eisen D: The clinical features, malignant potential, and systemic associations of oral lichen planus: a study of 723 patients. *J Am Acad Dermatol* 2002; **46**: 207 – 214.
- 11 McDonald I, Compston A: Associated diseases. In: *McAlpine's Multiple Sclerosis* (Compston A, ed). Edinburgh: Churchill Livingstone, 2006; pp 341 – 343.
- 12 Wekerle H, Lassmann H: The immunology of inflammatory demyelinating disease. In: *McAlpine's Multiple Sclerosis* (Compston A, ed). Edinburgh: Churchill Livingstone, 2006; pp 491 – 547.
- 13 Keate RF, Williams JW, Connolly SM: Lichen planus esophagitis: report of three patients treated with oral tacrolimus or intraesophageal corticosteroid injections or both. *Dis Esophagus* 2003; **16**: 47 – 53.
- 14 Fivenson DP, Mathes B: Treatment of generalized lichen planus with alefacept. *Arch Dermatol* 2006; **142**: 151 – 152.
- 15 Noseworthy J, Confavreux C, Compston A: The treatment of multiple sclerosis. In: *McAlpine's Multiple Sclerosis* (Compston A, ed). Edinburgh: Churchill Livingstone, 2006; pp 683 – 699.
- 16 Ismail SB, Kumar SK, Zain RB: Oral lichen planus and lichenoid reactions: etiopathogenesis, diagnosis, management and malignant transformation. *J Oral Sci* 2007; **49**: 89 – 106.
- 17 Davenport CB: Multiple sclerosis from the standpoint of geographic distribution and race. *Arch Neurol Psychiatry* 1922; **8**: 51 – 58.
- 18 Ghodsi SZ, Daneshpazhooh M, Shahi M, *et al*: Lichen planus and hepatitis C: a case-control study. *BMC Dermatol* 2004; **4**: 6.
- 19 Ramagopalan SV, Dymnt DA, Valdar W, *et al*: Autoimmune disease in families with multiple sclerosis: a population-based study. *Lancet Neurol* 2007; **6**: 604 – 610.
- 20 Barcellos LF, Kamdar BB, Ramsay PP, *et al*: Clustering of autoimmune diseases in families with a high-risk for multiple sclerosis: a descriptive study. *Lancet Neurol* 2006; **5**: 924 – 931.
- 21 Nielsen NM, Frisch M, Rostgaard K, *et al*: Autoimmune diseases in patients with multiple sclerosis and their first-degree relatives: a nationwide cohort study in Denmark. *Mult Scler* 2008; **14**: 823 – 829.
- 22 Henderson RD, Bain CJ, Pender MP: The occurrence of autoimmune diseases in patients with multiple sclerosis and their families. *J Clin Neurosci* 2000; **7**: 434 – 437.
- 23 Meiner Z, Zlotogorski A, Brautbar C: Pemphigus associated with multiple sclerosis. *Clin Exp Dermatol* 1992; **17**: 217.
- 24 Gorodkin R, Leahy B, Neary D, *et al*: Coexistence of systemic sclerosis and multiple sclerosis. *J Neurol* 2004; **251**: 1524 – 1525.

Author's address for correspondence

**Dr Smiljana Ristić**

Department of Biology and Medical Genetics, School of Medicine, University of Rijeka,  
Branchetta 22, CRO-51000 Rijeka, Croatia.

E-mail: ristics@medri.hr