

Stres fraktura tibije kod rukometaša

Miškulin, Mladen; Vrgoč, Goran; Kraguljac, Darko

Source / Izvornik: **Medicina Fluminensis : Medicina Fluminensis, 2013, 49, 98 - 105**

Journal article, Published version

Rad u časopisu, Objavljena verzija rada (izdavačev PDF)

Permanent link / Trajna poveznica: <https://um.nsk.hr/um:nbn:hr:184:419092>

Rights / Prava: [In copyright](#)/[Zaštićeno autorskim pravom.](#)

Download date / Datum preuzimanja: **2024-09-21**



Repository / Repozitorij:

[Repository of the University of Rijeka, Faculty of Medicine - FMRI Repository](#)



Tibial stress fracture in handball player

Stres fraktura tibije kod rukometaša

Mladen Miškulin¹, Goran Vrgoč^{1*}, Darko Kraguljac²

¹Department of Orthopaedic Surgery,
University Hospital Sveti Duh, Zagreb

²Department of Pediatric Physical Medicine
and Rehabilitation, University Hospital
Centre Rijeka, Rijeka

Primljeno: 14. 4. 2012.

Prihvaćeno: 26. 11. 2012.

Abstract. Aim: Authors present a misdiagnosed case of proximal tibial stress fracture emphasizing diagnostical and treatment methods. **Case report:** A 27-year-old international top-level handball player, presented to us with a stress fracture of the right proximal anterior tibia in connection with repetitive and excessive stress to lower leg. He plays right wing position and uses his right leg for jumping. There was no history of previous injuries. We used a new non-operative approach in treating a top-level handball player-as well as detailed diagnostic monitoring of both the injury and the recovery. Athlete's response to the new non-operative approach was excellent after having been misdiagnosed. Documented monitoring lasted for 3.5 years after the conservative treatment had been finished. **Conclusion:** The emphasis is put on the importance of making a diagnosis at the right time and choosing adequate treatment with the aim of reducing time needed for recovery and returning top-level athletes' performance to the same level as prior to injury. Based on a detailed search of relevant literature, the authors have found that stress fractures have never before been described in handball players.

Key words: handball player, non-operative treatment, proximal tibia, risk factors, stress fracture

Sažetak. Cilj: Autori predstavljaju slučaj pogrešne dijagnoze stres frakture proksimalnog dijela tibije s naglaskom na dijagnostičkim metodama i metodama liječenja. **Prikaz slučaja:** Vrhunski međunarodni rukometaš u dobi od 27 godina javio nam se sa stres frakturom prednje strane gornje trećine desne tibije, što je povezano s prekomjernim i repetitivnim stresom na potkoljenu. Igra poziciju desnog krila, te koristi desnu nogu za odskok. Sportaš nije imao prethodnih ozljeda. Koristili smo novi neoperativni pristup u liječenju vrhunskog rukometaša i proveli detaljno dijagnostičko praćenje ozljede i oporavka. Sportaš je izvrsno reagirao na neoperativni pristup liječenja nakon pogrešne dijagnoze. Dokumentirano praćenje trajalo je 3,5 godina, nakon što je završeno konzervativno liječenje. **Zaključak:** Naglasak je stavljen na važnost pravovremeno postavljene dijagnoze te odabir adekvatnog liječenja kako bi se smanjilo vrijeme potrebno za oporavak i vraćanje vrhunskog sportaša u formu jednaku onoj prije ozlijede. Nakon detaljnog pretraživanja relevantne literature autori nisu pronašli opis stres frakture kod rukometaša do sada.

Ključne riječi: faktori rizika, neoperativno liječenje, proksimalna tibija, rukometaš, stres fraktura

Corresponding author:

*Goran Vrgoč, MD

Department of Orthopaedic Surgery

University Hospital Sveti Duh

Sveti Duh 64, 10000 Zagreb

E mail: gvrhoc@gmail.com

<http://hrcak.srce.hr/medicina>

INTRODUCTION

Stress fractures are focal structural weaknesses in bones which are caused by repetitive and excessive stress to bones¹. They normally occur because of chronic skeletal overloading which lasts for a certain period of time which is not sufficient for bones to adapt appropriately². These type of fractures are most frequently seen in military and athletic populations³. Low quality nutrition and the way of living may increase the risk of stress fracture⁴. The most frequent locations for stress fractures are the tibia (23,6 percent), tarsal navicular (17.6 percent), metatarsal (16.2 percent), fibula (15.5 percent), femur (6.6 percent), pelvis (1.6 percent), and spine (0.6 percent)⁴. Different reports estimate tibial stress fracture to compose anywhere from 18.9 % to 63.0 % of all fractures in athletes⁵. This kind of injury in athletes requires a period without training and playing. Rehabilitation

lasts on average 12 ± 7 weeks depending on severity of the injury. Such a long period represents a problem for athletes because the recovery is too long to allow athletes to return to competitive training quickly and easily.

In this article we managed to show that handball players are as prone to this kind of injury as any other athletes. Modern sports are increasingly demanding for athletes what leads to more frequent injuries to musculoskeletal system. Thus, the task set before sports medicine is a challenging one. It strives to give athletes fast and complete recovery and return them to training as soon as possible. Early correct diagnosis and the

According to our knowledge, stress fractures also occur in handball players, which has not been described so far.

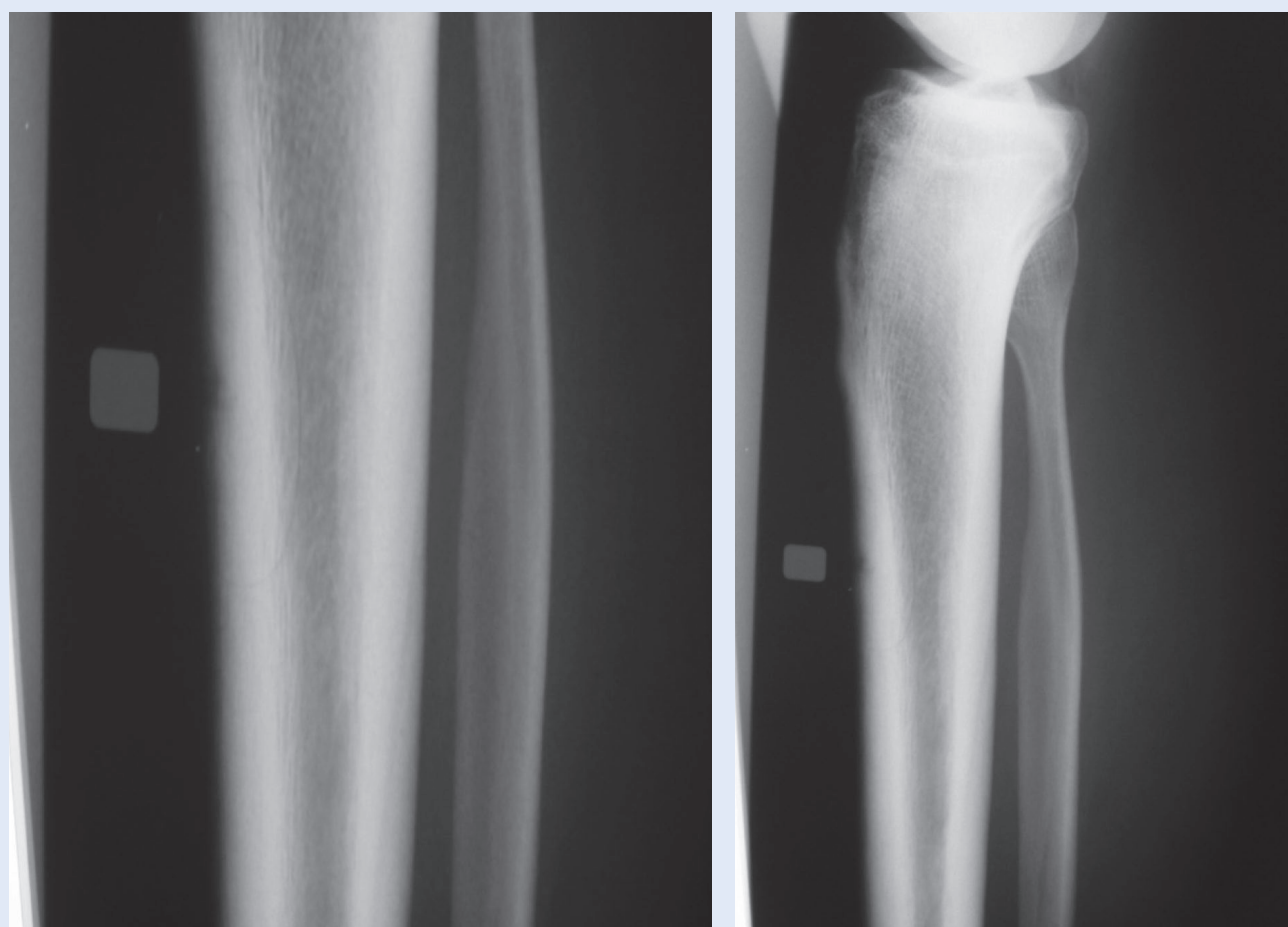


Figure 1 May 2007; X-ray of the right lower leg – in the area of ventral tibia, in proximal methaphysis, transparent focal point within the compact bone

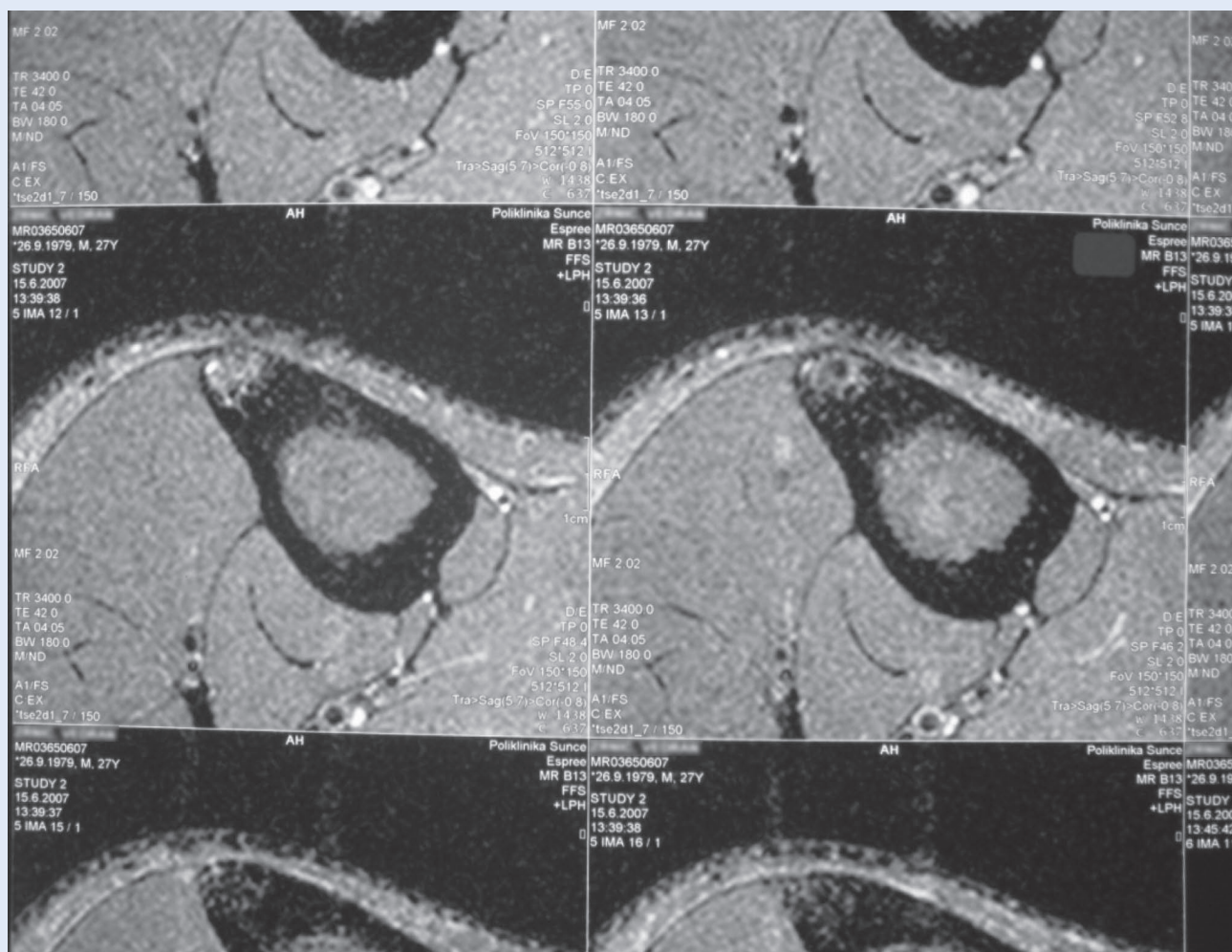


Figure 2 15 June 2007; MR scan of the right lower leg – in proximal anterior part of tibia there is zone of changed signal in the compact bone 1cm in radius. STIR and PD sequences show increased signal intensity, centrally stretched zone of moderately increased signal and peripherally vaguely outlined zone of discreetly increased signal. Within the described zone of increased signal, a small sclerotic zone without signal is displayed. T1 and T2 measure sequences show that the same area has only a minimally increased signal. While the change has an oval form on transversal layers, the formation takes an oblong form and is laid diagonally on the longer axis on the sagittal and coronal layers. Corticis appears to be in order, adjacent structures appear to be regular.

right choice of treatment method can significantly influence further professional progress of athletes.

CASE REPORT

We are reporting on the case of a 27-year-old international top level handball player, right wing position (position 1 in handball) World championship gold medalist in Portugal 2003 and Olympic gold medalist in Athens 2004, a man who is playing professional handball and is a national handball team member. The player had no history of injuries in handball except for classic contusion and bruises that have never

caused him any days off the field. The patient does not drink alcohol, does not smoke and is on a special sports diet. He trains two times a day.

The first symptoms appeared in February 2007 and manifested as pain in the upper part of the right lower leg. The pain would not recede when the player rested from activity (Figure 1). The pain worsened with time until the player asked for medical help 5 months after the first symptoms had appeared. During examination in July 2007 the player felt tenderness to palpation in the area of the proximal third of tibia and there was a localized swelling, but no changes

on the skin. In the moment of examination, X-ray scan (Figure 2) showed a radiotransparent focal point in the area of frontal corticalis of the proximal third of the right tibia what was an indication for a magnetic resonance imaging (MRI) scan. The findings showed a hypodensive zone localized in the same region as on X-ray findings, 13 mm in radius with vague borders; and sclerotic bone in the center. Considering the mentioned findings, the player was prescribed a 6-week sports activity restriction. By looking at the available club doctors' records, we did not find a diagnosis based on which they recommended therapy. A period of rest caused pain to recede so the player was allowed to return to training, initially straight-line running over a period of 7 days after which the player was allowed to return to specific handball training. At the beginning of 2007/08 handball season, in September 2007 the pain in the area of the right lower leg increased during training as well as during matches; the pain was sharp and piercing, localized in the upper third of the right lower leg and it disabled the player in training. It is important to note that, considering player's field position and the fact that he is a right winger, the right leg is extremely important in jumping. Team doctor indicated that further examination was necessary, in particular scintigraphy with technetium 99m (Tc 99m) and nuclear magnetic resonance (NMR) after which a diagnosis was made doubting on osteoid osteoma. Computed tomography (CT)-guided biopsy was indicated. The osteoid osteoma diagnosis was made based on the mentioned symptoms which did not respond adequately to therapy and based on changes shown on MRI and x-ray images. It can be noticed from available records that the therapeutic approach to injury was inadequate and incomplete as well as an undefined diagnosis made by club doctors. Pathological analysis of tissue excluded such a diagnosis and stress fracture of the tibial shaft was finally made. Post-operatively, the player was prescribed 6-week of rest and non-weight-bearing on the right leg for the first two weeks. After 2-3 months the pain worsened and the player had to stop

training. The team doctor recommended a different surgical procedure i.e. endomedullary osteosynthesis of the right lower leg. Player's withdrawal from training coincided with the winter period of the national team activities (European Championship in Norway in January 2008) so the player, after having been examined by the senior author, who at the time was the head doctor of the national handball federation, withdrew from the roster of the national handball team. The patient contacted the senior author for a second

Stress fractures are serious sports injuries which can go unnoticed for a long period of time and be incorrectly diagnosed or treated. It is very important to diagnose stress fracture in time and carry out adequate therapy to enable faster and more efficient treatment, and returning of a healthy player to the field.

opinion after having been prescribed numerous unsuccessful therapies. We first wanted additional radiological examination which showed a situation which was characteristic for a stress fracture of the right lower leg. By taking into consideration the mentioned symptoms, the age of the athlete, biomechanics of the sport that he practices and a detailed analysis of entire examinations we have made the diagnosis of midanterior tibial stress fracture. In agreement with the senior author, the patient opted for a conservative approach in treating his injury and underwent a rehabilitation treatment in the following protocol – continued physical therapy lasting four weeks with the use of standard therapeutic methods which include interferential currents, magnet, laser with cluster probe 1000 mW; as a novelty, Extracorporeal Shock Wave Therapy (ESWT)/10 Hz/2-3 bar was introduced, and it was repeated 5 times. The player repeated 4 weeks of rehabilitation in another specialized rehabilitation centre which continued with a similar treatment but without using ESWT. Because of the duration of the treatment, the player cancelled his participation in the Summer Olympic Games in Beijing.

In the control multislice computed tomography (MSCT), May 2008, after having completed the

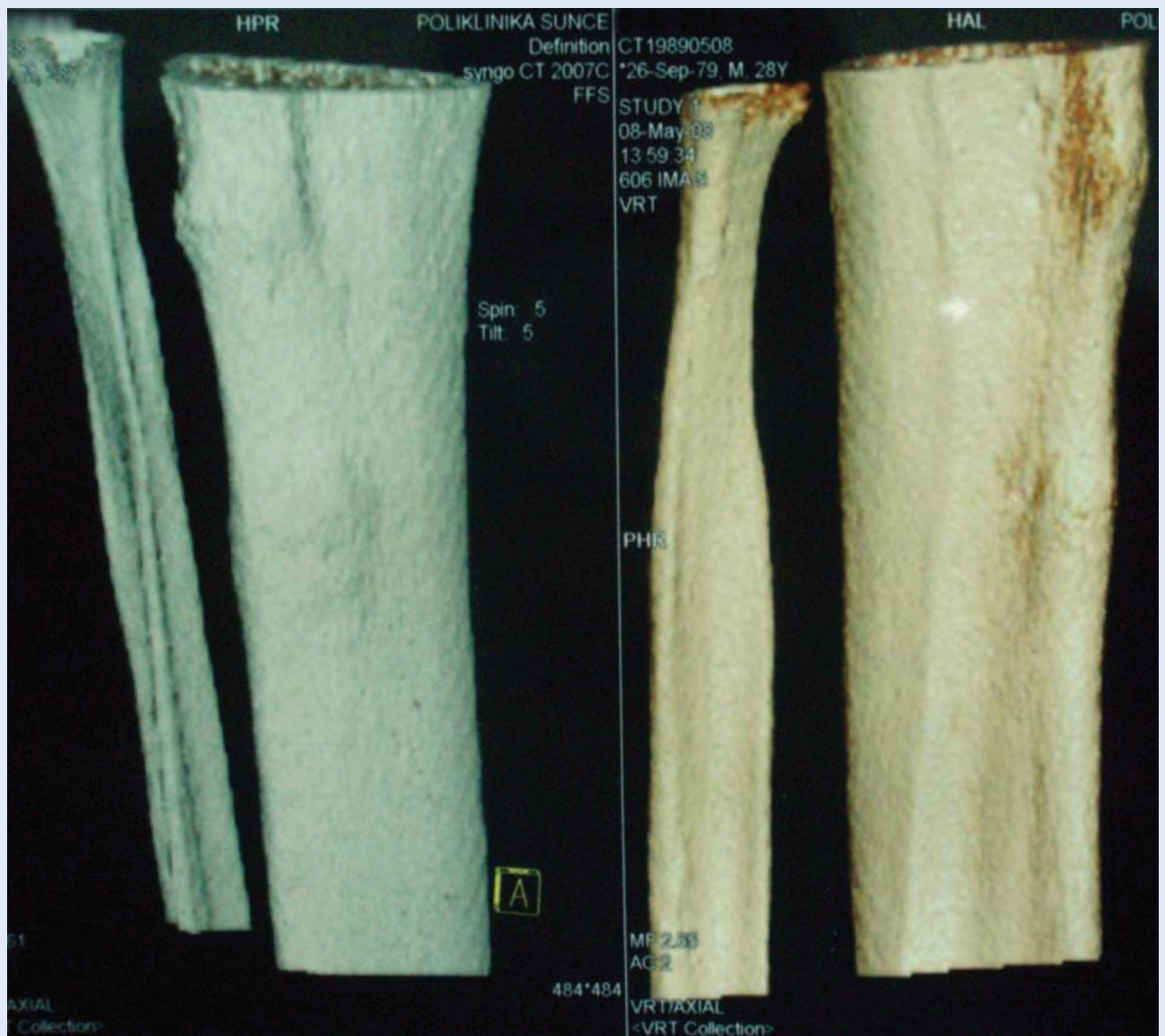

Figure 3 8 May 2008; MSCT axial layers of the right lower leg – 3D and MPR reconstructions, in comparison with a series of earlier scans, oval endostotic change of the ventricular corticalis of the right tibia is barely noticeable. The cross sections show that the earlier formation was much more sclerotic entirely compared to previous CT findings.

described therapeutic cycle, axial layers of the right lower leg – three dimensional (3D) and multiplaner reconstructions (MPR), compared to a series of earlier images, oval endostotic change in the ventricular corticalis of the right tibia is barely noticeable. In the cross sections the earlier formation was entirely much more sclerotic compared to the previous CT findings (Figure 3). During clinical examination, following the therapy, the player stated that he felt less pain in the upper part of tibia even after weight bearing on his leg.

In conclusion, tibial stress fracture caused athlete’s yearlong withdrawal and missing a whole season, neither playing at the Olympic Games nor the European Handball Championship due to a late diagnosis. Today, the patient still plays top level handball and he no longer experiences any difficulties or pain.

DISCUSSION

Handball is a team contact sport, popular worldwide but especially in Europe and Scandinavia. It owes its popularity to great dynamics and speed

as well as strength and skill in competing between the opposing physically extremely well-prepared players. By analyzing the literature, the authors have not found any data on stress fracture in handball players, although numerous studies have researched injuries in handball.

The explanation is simple to understand: when activity and stress on bone are increased, this increases the turnover rate of bone as it adapts to the increased forces. If the forces applied are too great, too frequent, and/or too long-standing, assuming they are not great enough to cause a frank fracture, they will result in a stress response or stress fracture in the bone⁶.

It has been reported that the frequency of stress fracture in athletes is 1.4 % – 4.4 %⁷.

In Iwamoto and Takeda study the highest proportion of stress fracture was seen with aerobics, classical ballet, rowing, track and field, basketball, volleyball, soccer, baseball, rugby, and tennis⁸. Apart from athletes and military recruits, stress fracture has increasingly been reported in recreational athletes. The rising popularity of running sports has led to an increase in lower extremity injuries. Recreational runners who run more than 25 miles per week are more prone to stress fractures^{9,10}, like athletes who participate in track and field, basketball, soccer, or dance^{11,12}. Although stress fractures can occur during almost any sports activity, swimming seems to be safe in this respect⁸. The rising concern of today's population regarding their physical fitness and appearance has led to an increase in the number of stress fractures in recreational athletes.

Most tibial stress fractures involve the posteromedial proximal and distal tibia¹³. Posterior tibial stress fractures are on the compression side of the tibia, which allows early response to rest and activity modification with an early return to sports³. Midanterior tibial stress fractures what we had in our case report are far less common, composing 2.4% of all stress fractures and 4.6% of tibial stress fractures. According to Authors' knowledge there was no report about the occurrence of tibial stress fractures in handball. According to our case their incidence is almost

equivalent as the one described in soccer players or soldiers¹⁴.

Tibial stress injuries include different types of bone lesions which can manifest in a number of abnormalities ranging from asymptomatic osteopenia to fracture all occurring as a consequence of abnormal repetitive stress which normal bone is exposed to^{13,15,16}. This range of lesions includes periostitis, cortical osteopenia, cancellous bone, and cortical fractures, which are often related to different degrees of reactive soft tissue and bone marrow edema^{13,15,16}.

It is very difficult to prevent these injuries because of a large number of factors which contribute to stress fractures. One study discovered lower 25-hydroxyvitamin D levels in Finnish male military recruits with stress fractures¹⁷. A research study of female military recruits showed an increased risk of stress fracture in those with a history of smoking, exercising less than three times per week, and drinking more than 10 alcoholic drinks per week before beginning of basic training¹⁸.

Risk factors for tibial stress fracture include age^{19,20}, gender^{19,21-23}, body weight²⁴, race²⁰, and training history²⁵⁻²⁷, while biomechanical parameters such as external rotation of the hip²² and vertical ground –reaction forces during running⁸ have also been associated with stress fractures. Pain, focal tenderness (65.9 to 100 percent) and edema usually manifest in patients at the site of injury during examination^{10,28}. We should confirm diagnosis with imaging methods.

The role of diagnostic imaging remains fundamental in detecting the cause of chronic lower leg pain²⁹. Radiography detects only a small number of stress fractures and it is hard to recognize them without using more sophisticated diagnostic imaging. MRI and CT are diagnostic tools with the highest sensitivity and specificity in the differential diagnosis of lower leg pain^{15,16}. We can also use a technetium 99m labeled bone scan.

In case of non-surgical treatment failure, operative management is another option. In a study carried out on 7 collegiate-level athletes, Varner and Younas have described 11 chronic anterior midtibial stress fractures treated with reamed intramedullary nailing. They were monitored for 17

months and they showed low complication rate. All patients returned to sports activity in 3-5 months' time³.

Many prevention methods for stress fractures were tested but without any significant results. We only found in one study that orthotics for example shock-absorbing shoe inserts proved to be effective in reducing the occurrence of lower extremity stress injury in military recruits³⁰. Calcium and vitamin D metabolism and supplementation may influence the prevention of stress fracture however the data are controversial⁴.

CONCLUSION

The aim of this case report was to show that stress fractures also occur in handball players, which has not been described so far in any article according to our knowledge. We can conclude that stress fractures are serious sports injuries which can go unnoticed for a long time as well as be incorrectly diagnosed and treated. It keeps athletes away from training and competition for a long period. It is very important to diagnose stress fracture in time and carry out adequate therapy which will enable a faster and more efficient treatment, and consequently returning of a healthy player to the field.

LITERATURE

- Burr DB, Milgrom C, Boyd RD, Higgins WL, Robin G, Radin EL. Experimental stress fractures of the tibia: biological and mechanical etiology in rabbits. *J Bone Joint Surg Br* 1990;72:370-5.
- Beck BR, Matheson GO, Bergman G, Norling T, Fredericson M, Hoffman AR et al. Do capacitively coupled electric fields accelerate tibial stress fracture healing? A randomized controlled trial. *Am J Sports Med* 2008;36:545-53.
- Varnier KE, Younas SA, Lintner DM, Marymont JV. Chronic anterior midtibial stress fractures in athletes treated with reamed intramedullary nailing. *Am J Sports Med* 2005;33:1071-6.
- Patel DS, Roth M, Kapil N. Stress fractures: diagnosis, treatment, and prevention. *Am Fam Physician* 2011;83:39-46.
- Bennell KL, Brukner PD. Epidemiology and site specificity of stress fractures. *Clin Sports Med* 1997;16:179-96.
- Coady CM, Micheli LJ. Stress fractures in the pediatric athlete. *Clin Sports Med* 1997;16:500-13.
- Monteleone GP Jr. Stress fractures in the athlete. *Orthop Clin North Am* 1995;26:423-33.
- Iwamoto J, Takeda T. Stress fractures in athletes: review of 196 cases. *J Orthop Sci* 2003;8:273-8.
- Clement DB, Ammann W, Taunton JE, Lloyd-Smith R, Jespersen D, McKay H et al. Exercise induced stress injuries to the femur. *Int J Sports Med* 1993;14:347-52.
- Matheson GO, Clement DB, McKenzie DC, Taunton JE, Lloyd-Smith DR, Macintyre JG. Stress fractures in athletes. A study of 320 cases. *Am J Sports Med* 1987;15:46-58.
- Brukner P, Bradshaw C, Khan KM, White S, Crossley K. Stress fractures: a review of 180 cases. *Clin J Sport Med* 1996;6:85-9.
- Ohta-Fukushima M, Mutoh Y, Takasugi S, Iwata H, Ishii S. Characteristics of stress fractures in young athletes under 20 years. *J Sports Med Phys Fitness* 2002;42:198-206.
- Anderson MW, Greenspan A. Stress fractures. *Radiology* 1996;199:1-12.
- Orava S, Hulkko A. Stress fracture of mid tibial shaft. *Acta Orthop Scand* 1984;55:35-7.
- Gaeta M, Minutoli F, Scribano E, Ascenti G, Vinci S, Bruschetta D et al. CT and MRI findings in athletes with early tibial stress injuries: comparison with bone scintigraphy and emphasis on cortical abnormalities. *Radiology* 2005;235:553-61.
- Gaeta M, Minutoli F, Vinci S, Salamone I, D'Andrea L, Bitto L et al. High-resolution CT grading of tibial stress reactions in distance runners. *AJR Am J Roentgenol* 2006;187:789-93.
- Ruohola JP, Laaksi I, Ylikomi T, Haataja R, Mattila VM, Sahi T et al. Association between serum 25(OH)D concentrations and bone stress fractures in Finnish young men. *J Bone Miner Res* 2006;21:1483-8.
- Lappe J, Davies K, Recker R, Heaney R. Quantitative ultrasound: use in screening for susceptibility to stress fractures in female army recruits. *J Bone Miner Res* 2005;20:571-8.
- Brudvig TJ, Gudger TD, Obermeyer L. Stress fractures in 295 trainees: a one-year study of incidence as related to age, gender and race. *Mil Med* 1983;148:666-7.
- Milgrom C, Simkin A, Eldad A, Nyska M, Finestone A. Using bone's adaptation ability to lower the incidence of stress fractures. *Am J Sports Med* 2000;28:245-51.
- Ashford R, Macleod M. Shin splits are symptoms, not a diagnosis: letters; authors replay to letters from editor. *Br Med J* 1999;318:1560.
- Gialdi M, Milgrom C, Simkin A, Danon Y. Stress fractures: identifiable risk factors. *Am J Sports Med* 1991;19:647-52.
- Protzman RR, Griffis CG. Stress fractures in men and women undergoing military training. *J Bone Joint Surg Am* 1977;59:825.
- Beck TJ, Ruff CB, Mourtada FA, Shaffer RA, Maxwell-Williams K, Kao GL et al. Dual-energy x-ray absorptiometry derived structural geometry for stress fracture prediction in male U.S. Marine Corps recruits. *J Bone Miner Res* 1996;11:645-53.
- Beck TJ, Ruff CB, Shaffer RA, Betsinger K, Trone DW, Brodine SK. Stress fracture in military recruits: gender differences in muscle and bone susceptibility factors. *Bone* 2000;27:437-44.
- Milgrom C, Finestone A, Shlamkovitch N, Rand N, Lev B, Simkin A et al. Youth is a risk factor for stress fracture: a

- study of 783 infantry recruits. *J Bone Joint Surg Br* 1994;76:20-2.
27. Swissa A, Milgrom C, Giladi M, Kashtan H, Stein M, Margulies J et al. The effect of pretraining sports activity on the incidence of stress fractures among military recruits: a prospective study. *Clin Orthop Relat Res* 1989; 245:256-60.
 28. Fredericson M, Bergman AG, Hoffman KL, Dillingham MS. Tibial stress reaction in runners. Correlation of clinical symptoms and scintigraphy with a new magnetic resonance imaging grading system. *Am J Sports Med* 1995;23:472-81.
 29. Gaeta M, Minutoli F, Mazziotti S, Visalli C, Vinci S, Gaeta F et al. Diagnostic imaging in athletes with chronic lower leg pain. *Am J Roentgenol* 2008;191: 1412-9.
 30. Rome K, Handoll HH, Ashford R. Interventions for preventing and treating stress fractures and stress reactions of bone of the lower limbs in young adults. *Cochrane Database Syst Rev* 2005;CD000450.